

Dr. Ülkem Cural

ORAL MAXILLOFACIAL SURGERY DDS, PHD

22 years old male patient referred to our clinic with fossa canine abscess. After clinic and radiographic examination cystic lesion detected at the right incisor area. Cyst enucleated immediately but unfortunately the related teeth had to be extracted. The pathologic investigation resulted as radicular cyst. After healing prosthetic rehabilitation discussed. The decision was Implant supported fixed prosthesis. but the residual bone was insufficient. The vestibular bone Wall was vanished and there was a dehiscence defect at the palatal Wall. 3D bone augmentation with mandibular ramus bone block graft was planned. 4 months after fist surgery implants were placed. Waited for 3 months for osteointegration and final prosthesis applied.

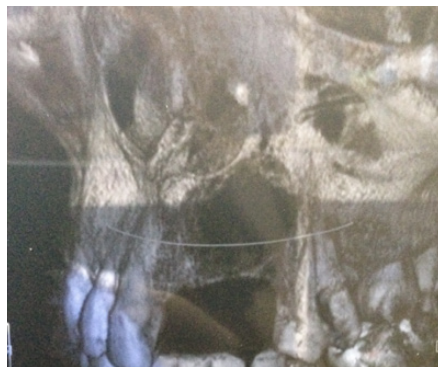

Photo 1: Bone defect after cyst enucleation

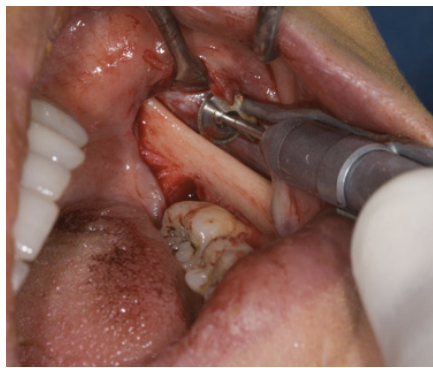


Photo 2: Harvesting bone block from ramus of mandibula

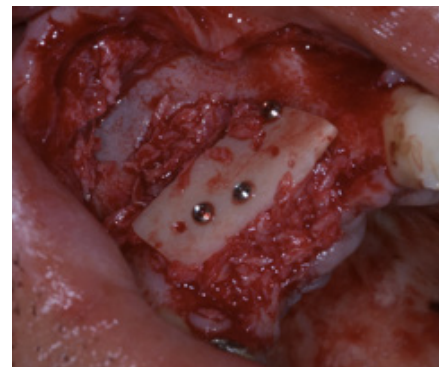


Photo 3 : Augmented defect area

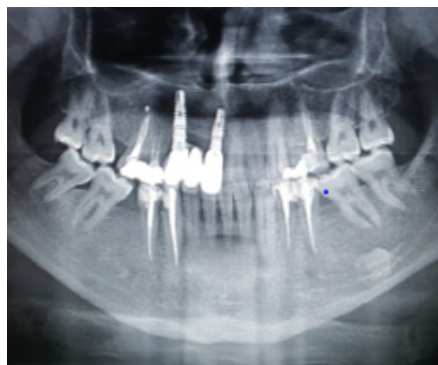


Photo 4: Radiography of implants with prosthetic rehabilitation

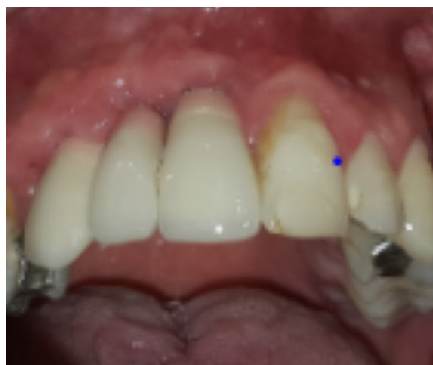

Photo 5: Final intra oral view